

Calipered Kinematically Aligned Total Knee Arthroplasty: An Accurate Technique That Improves Patient Outcomes and Implant Survival

STEPHEN M. HOWELL, MD

abstract

Kinematic alignment performed with caliper measurements and verification checks accurately co-align the femoral and tibial components with the 3 axes and joint lines of the native knee without ligament release and without restrictions on the degree of preoperative varus, valgus, flexion, and extension deformities and the degree of postoperative correction. [*Orthopedics*. 2019; 42(3):126-135.]

The term “kinematic alignment” indicates that the surgeon follows the philosophy of co-aligning the axes of the femoral and tibial components with the 3 axes of the native knee without releasing ligaments and without restrictions on the degree of preoperative varus, valgus, flexion, and extension deformities and postoperative correction.¹⁻⁵ The adoption of kinematic alignment is increasing. Three randomized trials and a national multicenter study showed that patients treated with kinematically aligned total knee arthroplasty (TKA) reported significantly better pain relief, function, and flexion and a more normal-feeling knee than patients treated with mechanically aligned TKA.^{2,6-12} Two randomized trials that limited the severity of the preoperative knee deformities showed similar clinical outcomes.^{13,14}

The Food and Drug Administration–approved “calipered” kinematic alignment technique uses verification checks to record caliper measurements of femoral and tibial bone resections that are adjusted within ± 0.5 mm of the thickness of femoral and tibial components after compensating for cartilage and bone wear and the 1-mm kerf from the saw cut (**Figure 1**). Caliper measurements verify that the components are aligned coincident to the native joint lines, which closely co-aligns the axes of the components with the 3 “kinematic” axes of the native knee (**Figure A**, available in the online version of this article).¹⁵ Adjusting the varus–valgus orientation, slope, and proximal–distal position of the tibial resection using decision trees for medial-pivot cruciate ligament retaining (CR) and cruciate ligament substituting (CS) inserts without releas-

ing ligaments balances the kinematically aligned TKA (**Figures 2-3**). Because measurements with a caliper are an inexpensive, basic, quick, and reproducible surgical skill, their use as a verification check should be considered when performing kinematic alignment with manual instruments, patient-specific guides, navigation, and robotics.^{5,15,16}

FIRST SURGICAL GOAL: RESTORE THE NATIVE JOINT LINES, Q-ANGLE, AND LIMB ALIGNMENTS UNIQUE TO EACH PATIENT

There is a growing body of evidence that a substantial number of native limbs do not have a neutral or 0° hip–knee–ankle (HKA) angle prior to the onset of osteoarthritis.¹⁷⁻²² The maximum range reported for the HKA angle is 7° to 12° for constitutional varus and -4° to -16° for constitutional valgus for individuals in the United States, Korea, India, and Belgium.^{17,18,20,22}

The author is from Adventist Health/Lodi Memorial Hospital, Lodi, and UC Davis, Sacramento, California.

The author has received grants from Medacta, Zimmer Biomet, and ThinkSurgical.

Correspondence should be addressed to: Stephen M. Howell, MD, 8120 Timberlake Way, Ste 112, Sacramento, CA 95823 (sebhowell@mac.com).

doi: 10.3928/01477447-20190424-02

Hence, when mechanical alignment changes constitutional varus and valgus alignment to a 0° HKA angle, the native joint lines and Q-angle are changed. Changing the native joint lines overly tensions or slackens the collateral, retinacular, and posterior cruciate ligaments and frequently creates an extension–flexion imbalance in a compartment that is uncorrectable with a soft tissue release (Figures 4-5).^{17,21,23-28} The technique of calipered kinematic alignment is highly reproducible, with the left to right symmetry of the distal lateral femoral angle, proximal medial tibial angle, Q-angle, and HKA angle restored to those of the native limb in more than 95% of patients with negligible risk of varus alignment of the tibial component with respect to the native tibial joint line.^{5,16}

SECOND SURGICAL GOAL: RESTORE LAXITIES, TIBIAL COMPARTMENT FORCES, AND KNEE ADDUCTION MOMENT OF THE NATIVE KNEE WITHOUT LIGAMENT RELEASE

Kinematic alignment restores the native laxities, tibial compartment forces, knee adduction moment, and gait without ligament release.^{19,27-32} The varus–valgus and internal–external rotation laxities of the native knee are looser at 45° and 90° of flexion than at 0° (Figure B, available in the online version of this article). The penalty for performing gap-balancing TKA, which tightens the native laxities at 45° and 90° to match those at 0° of flexion, is overly tight ligaments relative to those of the native knee that patients might perceive as pain, stiffness, and limited extension and flexion.^{28,33} Calipered kinematic alignment with a posterior CR implant restored 35 of 40 measures of laxity (8 laxities at 5 flexion angles from 0° to 120°) to those of the native knee.³⁰

Kinematic alignment without ligament release limits high compartment forces by restoring those of the native knee.^{27-29,31} There is no evidence of medial or lateral compartment overload, even

Figure 1: Verification checks consisting of serial calipered measurements of bone positions and resection thicknesses within ±0.5 mm of target are recorded intraoperatively on a worksheet. Recording these steps validates that the femoral and tibial components are kinematically aligned coincident to the native femoral and tibial joint lines before cementation. Abbreviations: ACL, anterior cruciate ligament; A/P, anterior/posterior; CR, cruciate ligament retaining; CS, cruciate ligament substituting; N, no; OA, osteoarthritis; PCL, posterior cruciate ligament; PF, patellofemoral; TKA, total knee arthroplasty; V-V, varus-valgus, Y, yes. (Image courtesy of Medacta.)

in the subset of patients with alignment of the tibial joint line and limb in a varus or valgus outlier range according to mechanical alignment criteria.²⁸ In contrast, the medial and lateral tibial compartment forces after mechanical alignment and ligament release to a 0° HKA angle with measured resection and gap-balancing

techniques are 3 to 6 times higher than those of the native knee and kinematically aligned TKA at 0°, 45°, and 90° of flexion.^{26,28,31,34}

Kinematic alignment results in a lower knee adduction moment than mechanical alignment, and this is one explanation for the negligible risk of varus failure of the

DECISION-TREE FOR BALANCING A CALIPERED KINEMATICALLY ALIGNED MEDACTA GMK SPHERE CR TKA					
Tight in Flexion & Extension	Tight in Flexion Well-Balanced in Extension	Tight in Extension Well-Balanced in Flexion	Well-Balanced in Extension and Loose in Flexion	Tight Medial & Loose Lateral in Extension	Tight Lateral and Loose Medial in Extension
Recut tibia and remove 1-2mm more bone.	Increase posterior slope until exposure A-P offset is restored at 90° of flexion.	Remove posterior osteophytes. Strip posterior capsule. Insert trial components & gently manipulate knee into extension.	Add thicker insert and recheck knee extends fully. When knee does not fully extend check PCL tension. When PCL is incompetent use GMK Sphere CS insert.	Remove medial osteophytes. Reassess. Recut tibia in 1-2° more varus. Insert 1 mm thicker insert.	Remove lateral osteophytes. Reassess. Recut tibia in 1-2° more valgus. Insert 1 mm thicker insert.

Figure 2: The decision tree lists 6 corrective measures for balancing the kinematically aligned total knee arthroplasty (TKA) with a posterior cruciate ligament retaining (CR) sphere insert. The balancing steps adjust the proximal–distal level and varus–valgus and slope orientations of the tibial resection and insert thickness without re-cutting the femur or releasing the collateral, retinacular, and posterior cruciate ligaments (PCL). Abbreviations: A-P, anterior-posterior; CS, cruciate ligament substituting. (Image courtesy of Medacta.)

DECISION-TREE FOR BALANCING A CALIPERED KINEMATICALLY ALIGNED MEDACTA GMK SPHERE CS TKA					
Tight in Flexion & Extension	Tight in Flexion Well-Balanced in Extension	Tight in Extension Well-Balanced in Flexion	Well-Balanced in Extension and Loose in Flexion	Tight Medial & Loose Lateral in Extension	Tight Lateral and Loose Medial in Extension
Recut tibia and remove 1-2mm more bone.	Confirm complete resection of the PCL. Increase posterior slope until natural A-P offset is restored at 90° of flexion.	Remove posterior osteophytes. Strip posterior capsule. Insert trial components & gently manipulate knee into extension.	Add thicker insert and recheck knee extends fully. If still loose in flexion, then reduce slope or resect 1-2 mm bone from distal femur and add thicker GMK Sphere CS insert.	Remove medial osteophytes. Reassess. Recut tibia in 1-2° more varus. Insert 1 mm thicker insert.	Remove lateral osteophytes. Reassess. Recut tibia in 1-2° more valgus. Insert 1 mm thicker insert.

Figure 3: The decision tree lists 6 corrective measures for balancing the kinematically aligned total knee arthroplasty (TKA) with a posterior cruciate ligament substituting (CS) sphere insert. The balancing steps adjust the proximal–distal level and varus–valgus and slope orientations of the tibial resection and insert thickness without releasing collateral, retinacular, and posterior cruciate ligaments (PCL). On the rare occasion that the resection of the PCL excessively loosens the flexion space relative to the extension space, resect 1 to 2 mm of bone from the distal femur using a re-cut guide insert and add a thicker insert. Abbreviation: A-P, anterior-posterior. (Image courtesy of Medacta.)

tibial component 2 to 10 years after kinematically aligned TKA.^{35,36} The key surgical step of restoring the native joint line obliquity lowers the peak knee adduction moment during gait and better restores normal gait.^{11,19,37} Hence, kinematic alignment is a promising option in limbs with constitutional varus alignment and large coronal bowing of the tibial shaft because the low knee adduction moment and close to normal gait lower the risk of medial compartment overload.¹⁹

CALIPERED TECHNIQUE FOR SETTING THE FEMORAL COMPONENT COINCIDENT TO THE NATIVE FEMORAL JOINT LINE WITH VERIFICATION CHECKS

The following sequence of surgical steps, calipered measurements and adjustments, and the intraoperative recording of these measurements on a verification worksheet set the proximal–distal position and varus–valgus orientation of the femoral component coincident to the native distal joint line at 0° and the anterior–

posterior position and internal–external orientation of the femoral component coincident to the native posterior joint line at 90° with high reproducibility (**Figure 1**).^{5,38,39} The femoral mechanical axis, transepicondylar axis, and anterior–posterior axis (Whiteside’s line) are not of interest or use when kinematically aligning the femoral component.^{3,18,23,24,40,41}

The knee is flexed to 90° and exposed using a medial approach. The short arm of the offset caliper is positioned against the distal medial femoral condyle and the long arm is positioned against the anterior tibia (**Figure 6**). The long arm is oriented parallel to the patella tendon. The distance of the offset is measured. When cartilage is worn to bone on the medial femoral condyle, 2 mm is subtracted.⁴²

Verification Check 1

The offset measurement is recorded on an electronic or a paper version of the verification worksheet (**Figure 1**). During final balancing before cementation of the components, adjustments are made to the slope of the tibial resection and insert thickness until the offset is matched within 0±1 mm, which restores the native laxities and tibial compartment forces of the flexion space (**Figure B**).^{30,42,43}

The knee is fully exposed, and the locations of cartilage wear on the distal femur are assessed. Any partially worn cartilage is removed to bone with a ring curette. The flexion–extension orientation of the femoral component is set by starting the diameter hole for the positioning rod midway between the top of the intercondylar notch and the anterior cortex (**Figure C**, available in the online version of this article). A 5- to 10-mm bridge of bone is kept between the posterior rim of the drill hole and the top of the intercondylar notch. The drill is oriented perpendicular to a plane coincident to the distal surface of the femur and parallel with the anterior cortex of the femur. A positioning rod is then inserted 8 to 10 cm.

Verification Check 2

A 5- to 10-mm bridge of bone is kept between the posterior rim of the drill hole and the top of the intercondylar notch. This limits flexion of the femoral component to within $1^\circ \pm 2^\circ$ with respect to the anatomic axis of the distal femur, resulting in a negligible risk of patellofemoral instability.⁴⁴⁻⁴⁶

The proximal–distal position and varus–valgus orientation of the femoral component are set by using an offset distal referencing guide (Figure 7). The offset of the guide is selected so that a compensation of 2 mm is added to the distal femoral condyle(s) with cartilage wear. Distal femoral bone wear is not corrected for because it is negligible even in the most arthritic knees.^{42,47} The selected offset distal referencing guide is slid over the intramedullary rod. It must be confirmed that the offset surface of the guide contacts both distal femoral condyles. The guide is pinned and the distal femur is resected. The thicknesses of the distal medial and lateral bone resections are measured with a caliper. The resections of the distal femur are adjusted until their thicknesses match the distal condyles of the femoral component within ± 0.5 mm after compensating for 2 mm of cartilage wear and a 1-mm kerf from the saw cut. A 1- or 2-mm underresection of the distal femoral condyles is corrected by removing more bone from the distal femur with the use of a 1-mm distal re-cut guide or by repositioning the distal femoral resection guide 2 mm more proximal. A 1- or 2-mm overresection of a distal femoral condyle is corrected by filling the gap by placing a 1- or 2-mm thick washer on the corresponding fixation peg of the 4-in-1 block.

Verification Check 3

The calipered measurements are recorded on the verification worksheet (Figure 1). The calipered measurements restore the varus–valgus orientation of the femoral component to the contralateral native limb in 97% of subjects.⁵

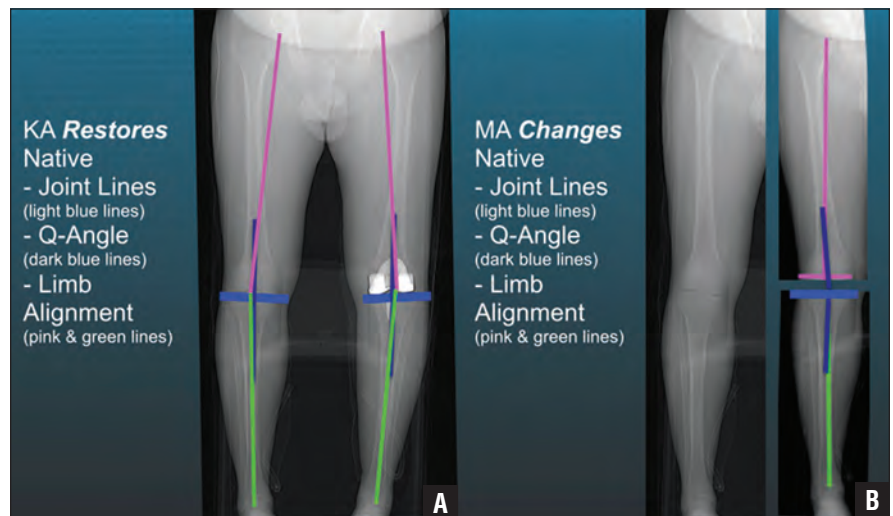


Figure 4: Composite of a patient with a constitutional varus limb (A) showing that calipered kinematic alignment (KA) restored the native joint lines (light blue lines), Q-angle (dark blue lines), distal lateral femoral angle (pink lines), and proximal medial tibial angle (green lines) in the limb with the total knee arthroplasty without ligament release (B). Abbreviation: MA, mechanical alignment.

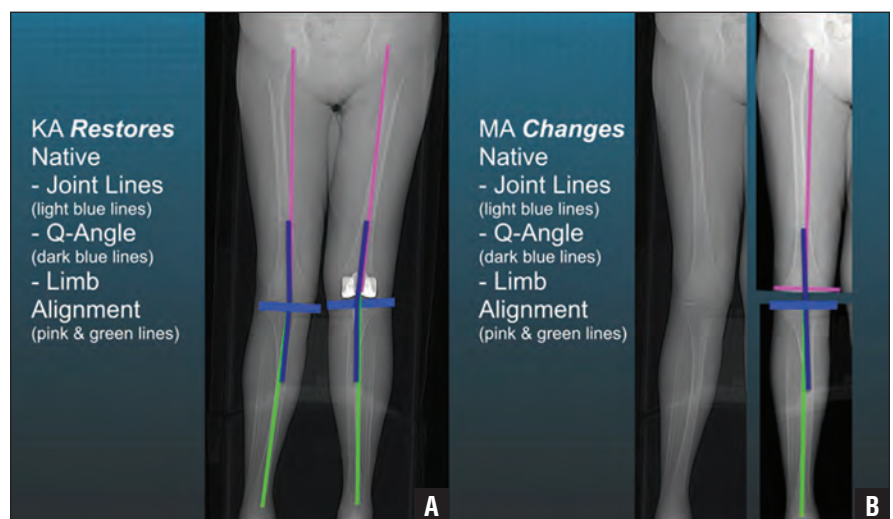


Figure 5: Composite of a patient with a constitutional valgus limb (A) showing that calipered kinematic alignment (KA) restored the native joint lines (light blue lines), Q-angle (dark blue lines), distal lateral femoral angle (pink lines), and proximal medial tibial angle (green lines) in the limb with the total knee arthroplasty without ligament release (B). Abbreviation: MA, mechanical alignment.

The anterior–posterior position and internal–external orientation of the femoral component are set by selecting a posterior referencing guide set in 0° rotation and positioning the feet of the guide in contact with the posterior femoral condyles (Figure 8). In the most varus osteoarthritic knee, the use of the 0° posterior referencing guide is correct because complete cartilage wear is rare on the posterior me-

dial femoral condyles. In the most severe valgus osteoarthritic knee, the 0° posterior referencing guide occasionally requires rotation of the foot of the guide 1 to 2 mm posterior from the worn posterior lateral femoral condyle. Posterior femoral bone wear is not corrected for because it is negligible even in the most arthritic knees.^{42,47}

The femoral component is sized by positioning the stylus on the anterior fe-

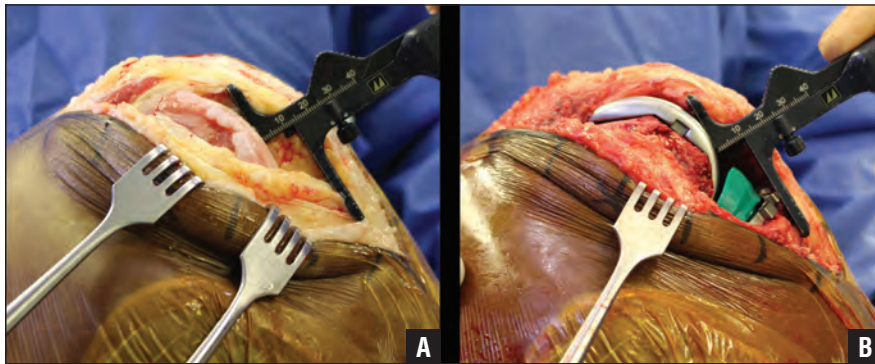


Figure 6: Intraoperative photographs of a right knee in 90° of flexion showing the caliper measurement of the “offset” of 13 mm between the distal medial femur and the anterior tibia at the time of exposure with the longer arm of the caliper oriented parallel to the patella tendon in the sagittal plane (A). When cartilage is worn to bone, 2 mm is subtracted from the measurement. During final balancing before cementation of the components, the slope of the tibial resection and insert thickness are adjusted until the offset with trial components matches the corrected offset of the knee at the time of exposure of 11 mm and passive internal–external rotation of the tibia is approximately $\pm 14^\circ$ like the native knee (B).³³ A 2° increase in the posterior slope and a 2-mm decrease in the insert thickness translate the tibia approximately 3 mm posterior (B).^{31,50}

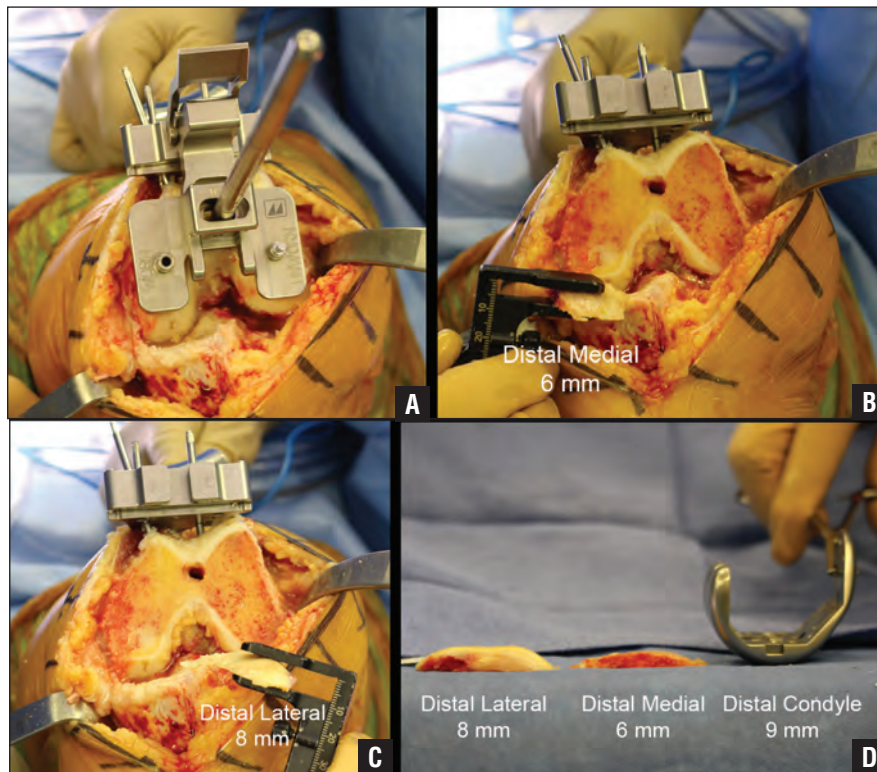


Figure 7: Composite of a left varus osteoarthritic knee showing the steps for kinematically aligning the femoral component coincident to the distal joint line of the native femur. The offset distal femoral resection guide is pinned with the ‘WORN’ mark overlying the medial femoral condyle and the ‘UNWORN’ mark overlying the lateral femoral condyle (A). The distal medial resection is measured with a caliper (B). The distal lateral resection is measured with a caliper (C). The distal condyles of the femoral component are 9 mm thick (D). Hence, the distal medial and lateral femoral resections should be 6 and 8 mm thick, respectively, compensating for the 1 mm of kerf of the saw and the 2 mm of cartilage wear on the distal medial femoral condyle. Recording these caliper measurements verifies that the proximal–distal position and varus–valgus orientation of the femoral component are coincident to the native joint line and match the contralateral native limb in 97% of subjects.⁵

mur. The holes are drilled for the 4-in-1 chamfer block. The 4-in-1 chamfer block is inserted, with a 1- or 2-mm thick washer placed on the corresponding fixation peg to correct for a 1- or 2-mm overresection of a distal femoral condyle. The posterior resections are made before the anterior and chamfer cuts are made. The thicknesses of the distal medial and lateral bone resections are measured with a caliper. The resections of the posterior femur are adjusted until their thicknesses match the posterior condyles of the femoral component within ± 0.5 mm after compensating for 2 mm of cartilage wear when present and a 1-mm kerf from the saw cut. When a posterior femoral resection is 1 to 2 mm too thick or too thin, the pin hole is elongated in the direction of the correction and the 4-in-1 chamfer block is translated as needed. The oblique compression screws are inserted and the reposition of the chamfer block is secured. The anterior and chamfer femoral resections are made.

Verification Check 4

The caliper measurements are recorded on the verification worksheet (Figure 1). The caliper measurements reproducibly restore the internal–external orientation of the femoral component within $0^\circ \pm 1.1^\circ$ of the posterior joint line and the flexion–extension plane of the native knee.³⁸

CALIPERED TECHNIQUE FOR SETTING THE TIBIAL COMPONENT COINCIDENT TO THE NATIVE TIBIAL JOINT LINE WITH VERIFICATION CHECKS

The following sequence of surgical steps and caliper measurements and adjustments verify that the proximal–distal position and the varus–valgus, flexion–extension, and internal–external orientations of the tibial component are coincident to the native tibial joint line. The tibial mechanical axis, intramedullary canal, and tibial tubercle are not of interest or use when kinematically aligning the tibial component.^{5,24,35,41,48}

An extramedullary tibial guide is used as a support for positioning the tibial resection guide, not as a method for referencing the ankle (**Figure 9**). The varus–valgus orientation of the tibial resection guide is set parallel to the articular surface of the native tibia by translating the medial–lateral slider at the ankle 12.5 mm lateral, which achieves an anatomic or approximately 2° to 3° varus orientation to the tibial mechanical axis in most patients.^{2,14} A conservative proximal–distal position is set for the tibial resection by positioning the tips of the two styluses with the 8-mm offset at the base of each tibial spine in an area with intact cartilage. An angel wing is inserted on the medial side of the tibial cutting guide. The slope of the resection of the medial tibial plateau is set by adjusting the anterior–posterior slider at the ankle until the plane of the angel wing is parallel with the medial tibial joint line after compensating for cartilage and bone wear. The internal–external orientation is set by rotating the tibial cutting guide until the line on the top is parallel to a line drawn between the tibial spines and a line representing the major axis of the elliptical shaped lateral tibial condyle.³⁸ The varus–valgus and slope orientation of the tibial resection guide are visually fine-tuned to compensate for cartilage and bone wear. The guide is pinned and the proximal tibia is resected. The medial edge of the tibial resection is examined to confirm that the plane of the tibial resection parallels the plane of the articular surface of the tibia after compensating for wear. A caliper is used to measure the thickness of the medial and lateral tibial condyles at the base of the tibial spines, which should be similar within 0 ± 0.5 mm (**Figure D**, available in the online version of this article).

Verification Check 5

The calipered measurements are recorded on the verification worksheet (**Figure 1**). The knee is flexed to 90°. The tightest fitting spacer block (choosing from 10, 11, 12, 13, and 14 mm) is inserted between the femur and the tibia.

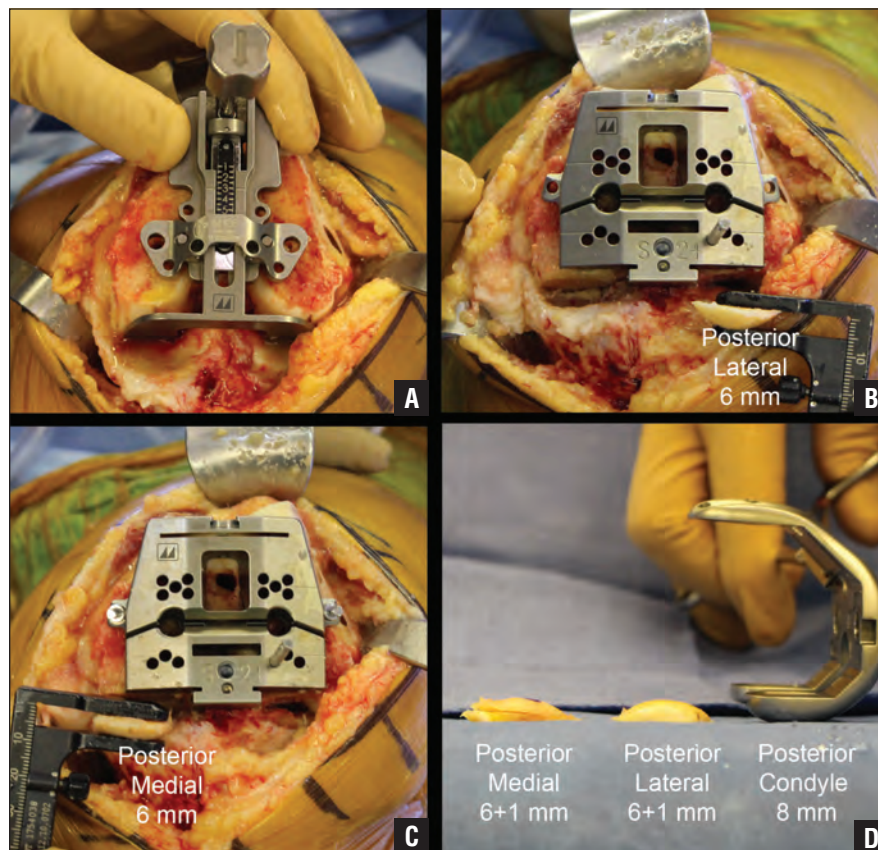


Figure 8: Composite of a left varus osteoarthritic knee showing the steps for kinematically aligning the femoral component coincident to the posterior joint line of the native femur. A posterior referencing guide set at 0° rotation is inserted and holes for a 4-in-1 chamfer block are drilled (A). The posterior lateral resection is measured with a caliper (B). The posterior medial resection is measured with a caliper (C). Hence, the posterior medial and lateral resections should be 7 mm thick, which compensates for the 1-mm kerf of the saw (D). The +1 indicates that 1 mm of additional bone was resected to correct a saw blade that skived during the initial posterior resection. Recording these calipered measurements verifies that the anterior–posterior position and internal–external orientation of the femoral component are coincident to the posterior joint line of the native knee within $0^\circ\pm 1.1^\circ$.³⁸

The tibia is re-cut using the 2-mm re-cut guide when the flexion space is too tight for a 10-mm spacer.

Verification Check 6

The spacer is internally and externally rotated with the knee in 90° of flexion and the relative tightness between the medial and the lateral compartments is assessed. It must be confirmed that the spacer fits tighter in the medial compartment, fits looser in the lateral compartment, and pivots about the medial compartment, which restores a trapezoidal flexion space like the native knee (**Figure B**).³³

The knee is placed in full extension. The spacer is re-inserted. The soft tissues are retracted and the varus–valgus laxity between the femoral resection and the spacer block and between the spacer block and the tibial resection is visually examined. It must be confirmed that the varus–valgus laxity is negligible and that the difference in the gaps between the medial and the lateral compartments is within 0 ± 0.5 mm. Overresections of the distal femoral condyle must be accounted for. When the varus–valgus laxity is greater in either the medial or the lateral compartment, one of the corrective steps listed in the decision trees must be performed

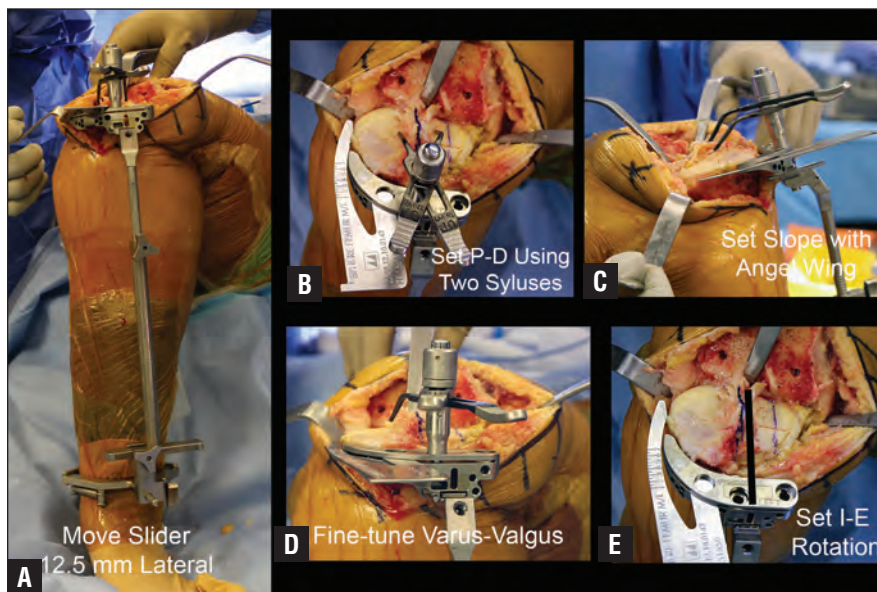


Figure 9: Composite of a right knee showing the steps for kinematically aligning the tibial component. The varus–valgus position of the tibial resection is set by applying a conventional extramedullary tibial resection guide to the ankle and moving the slider 12.5 mm lateral from the 0-mm position (A). The proximal–distal position is set by registering the tips of the two styluses at the base of each tibial spine in an area with intact cartilage (B). The slope is set by adjusting the anterior–posterior slider at the ankle until the plane of the angel wing is parallel to the medial tibial joint line after compensating for cartilage and bone wear (C). The varus–valgus and slope orientation of the tibial resection guide are fine-tuned to compensate for cartilage and bone wear (D). Internal–external orientation is set by rotating the tibial cutting guide until the line on the top of the guide is parallel to a line drawn between the tibial spines (black line) and a line representing the major axis of the elliptical shaped lateral tibial condyle (faint blue line) (E).

(**Figures 2-3**). When the lateral compartment is 2 mm tighter, the tibia must be re-cut using the 2° valgus re-cut guide. When the medial compartment is 2 mm tighter, the tibia must be re-cut using the 2° varus re-cut guide. When a 1-mm correction is required, the approximately 1-mm thick angel wing should be placed between the re-cut guide and the tibia resection and a 1° re-cut should be made.

Verification Check 7

Negligible varus–valgus laxity restores the native rectangular extension space and tibial joint line, knee, and limb alignment (**Figure B**).^{5,16,29,33,38}

The entire surface of the proximal tibial resection should be viewed to size and position the anatomic tibial baseplate (GMK Sphere; Medacta International SA, Castel San Pietro, Switzerland) (**Figure E**, available in the online version of this article). The anatomic shapes of the 6 trial tibial

baseplates closely match those of 7 kinematic tibial templates, which reproducibly set internal–external rotation of the tibial component within 0°±4° of the flexion–extension plane of the native knee.⁴⁹ The largest trial tibial baseplate that fits within the cortical boundary of the tibial resection is selected. The trial tibial baseplate is rotated until its edge is parallel with the cortex. The trial tibial baseplate is pinned and the slot for the stem is created.

Verification Check 8

Setting the internal–external rotation of the anatomic tibial baseplate to within 0°±4° of the flexion–extension plane of the knee restores high-level knee function.^{38,49} Because the mediolateral location of the tibial tubercle varies, the medial border and medial one-third of the tibial tubercle are unreliable landmarks for setting the rotation of the tibial component on the tibia.⁴⁸

Finally, trial components are inserted and the varus–valgus laxities with the knee in full extension and 15° to 20° of flexion and the anterior offset of the tibia on the medial femur, internal–external rotation, and posterior and distraction translation of the tibia with the knee in 90° of flexion are assessed while referring to the corrective measures in the sphere CR and sphere CS decision trees (**Figures 2-3**). The common principle of these decision trees is that fine-tuning the proximal–distal position and the varus–valgus and flexion–extension (slope) orientations of the tibial resection balances the knee. Balancing is accomplished without ligament release.

Final Verification With Trial Components Check 9

The knee is placed in full extension. The soft tissues are retracted and the varus–valgus laxity between the femoral component and the tibial insert is visually examined, which should be negligible like the native knee (**Figure B**).^{33,43} A 1° varus or a 1° valgus instability should be corrected because this degree of laxity is greater than the native knee and is associated with instability in extension.³³

The knee is placed in 15° to 20° of flexion. Varus–valgus laxity should be checked. The medial side should open approximately 1 mm and the lateral side approximately 2 to 3 mm and be looser than in full extension (**Figure B**). When the lateral side opens more than approximately 3 to 4 mm, it must be verified that the tibial resection is not in excessive valgus by re-measuring the tibial resection at the base of the tibial spines.

The knee is placed in 90° of flexion. When the posterior cruciate ligament is intact and the CR insert is used, the slope of the tibial resection and the thickness of the insert should be adjusted until the anterior offset of the tibia from the distal medial femoral condyle matches the knee at the time of exposure. A 2° increase in the posterior slope and a 2-mm decrease in the insert thickness translate the tibia approximately 3 mm posterior.^{31,50} It must be confirmed that the tibia

internally and externally rotates approximately $\pm 14^\circ$ like the native knee (**Figure 2** and **Figure B**).^{33,42} When the posterior cruciate ligament is resected and the CS insert is used, the posterior drawer must be checked and the tibia distracted. When the insert rides too posterior on the femoral component and the flexion space is slack, a thicker insert should be used and the flexion space tightened. When the thicker insert limits knee extension, 1 to 2 mm more bone should be re-cut from the distal femur. The corrective steps in the fourth column of the sphere CS decision tree should be followed (**Figure 3**).

KINEMATIC ALIGNMENT HAS A LOW RISK OF TIBIAL COMPONENT FAILURE, LOW RISK OF PATELLA INSTABILITY, AND HIGH IMPLANT SURVIVAL AT 10 YEARS

Calipered kinematic alignment effectively treats patients with severe preoperative varus and valgus deformities (**Figure 10** and **Figures F-G**, available in the online version of this article). Accurately setting the slope of the tibial component in the sagittal plane results in negligible failure of the tibial component after kinematic alignment.^{35,36,51,52} At 2 to 9 years of follow-up, the 0.3% incidence of tibial component failure (8 of 2725 prostheses) of patients treated with kinematically aligned TKA was comparable to, if not lower than, the 1.0% (54 of 5342 prostheses) incidence of failure from aseptic loosening of the femoral and/or tibial component reported for patients treated with mechanically aligned TKA.⁵³ In kinematic alignment, posterior subsidence or posterior edge wear is the mechanism of tibial component failure, which is caused by resecting the tibia in 7° greater slope than native.³⁶ In mechanical alignment, varus or medial overload is the mechanism of tibial component failure, which is caused by uncorrectable instability in a compartment from changing the constitutional limb alignment to neutral and a high knee adduction moment during gait.^{19,21,23,24} Hence, restoring the slope of the native tibial joint line lowers the risk

of posterior subsidence and posterior edge wear of the tibial component when performing kinematically aligned TKA.^{35,36}

Three biomechanical advantages explain the negligible risk of varus tibial loosening after kinematically aligned TKA. First, kinematic alignment provides more physiological strains in the collateral ligaments than mechanically aligned TKA by restoring the native joint lines and constitutional alignment without releasing ligaments.²⁵ Second, kinematic alignment provides medial and lateral tibial compartment forces comparable to those of the native knee with no evidence of tibial compartment overload even when the postoperative alignments of the limb, knee, and tibial component are within the varus or valgus outlier range according to mechanical alignment criteria.^{27,28,31} Third, kinematic alignment is an especially promising option for patients with large varus coronal bowing of the tibia because the knee adduction moment and risk of varus overload are lower than after mechanically aligned TKA.¹⁹

Accurately setting the flexion of the femoral component in the sagittal plane results in negligible patellofemoral instability after kinematic alignment.^{44,46} At 1 to 10 years of follow-up, there is a 0.4% incidence of patellofemoral instability (13 of 3212 prostheses) in patients treated with kinematically aligned TKA. In kinematic alignment, flexion of the femoral component greater than 10° with respect to the anatomic axis of the distal femur increased the risk of patellofemoral instability because of downsizing the femoral component approximately 1 to 2 sizes, reducing the cross-sectional area of the trochlea, reducing the proximal reach of the flange by approximately 8 mm, and delaying the engagement of the patella during early flexion.^{44,46} A change in the native Q-angle does not cause patellofemoral instability because kinematic alignment restores the native Q-angle, whereas mechanical alignment increases or decreases the native Q-angle in limbs

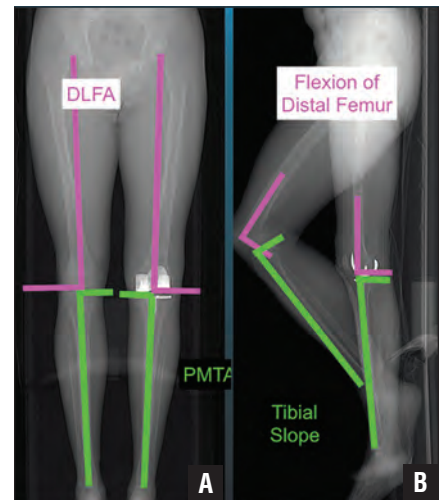


Figure 10: Composite showing that calipered kinematic alignment restored the distal lateral femoral angle (DLFA) and proximal medial tibial angle (PMTA) of the total knee arthroplasty to those of the native knee in the sagittal plane (A) and the flexion-extension orientation of the distal femoral joint line and the proximal tibial joint line of the total knee arthroplasty to those of the native knee in the coronal plane (B).

with varus or valgus constitutional alignment, respectively (**Figures 4-5**).²¹ The design of the femoral component does not cause patellofemoral instability because kinematic alignment more closely restores the groove location and the sulcus angle of the native trochlea and trochlea morphology without overstuffing than mechanical alignment.^{54,55} Internal rotation about the center of the femoral component of approximately 3° relative to mechanical alignment does not cause patellofemoral instability because the approximately 1.5-mm increase in the distance between the lateral prosthetic trochlea and the lateral femur is negligible.⁴⁴ The use of a distal referencing guide attached to an intraosseous positioning rod limits flexion of the femoral component to $1^\circ \pm 2^\circ$ with respect to the femoral anatomic axis, which is 9° less than patients with patellofemoral instability (**Figure C**).⁴⁵ Hence, limiting flexion of the femoral component lowers the risk of patellofemoral instability when performing kinematically aligned TKA.⁴⁶

The 10-year implant survivorship of a single-surgeon series of kinematically

aligned TKAs performed without restricting the degree of preoperative varus–valgus and flexion deformity was comparable to, if not higher than, that of two single-surgeon series of mechanically aligned TKA. Using aseptic revision at 10 years as the endpoint, the 98.5% implant survival after 220 kinematically aligned TKAs was 5.5% higher than the approximately 93% implant survival after 398 mechanically aligned TKAs in the United States,⁵⁶ and 4.5% higher than the approximately 94% implant survival after 270 mechanically aligned TKAs in the United Kingdom.⁵⁷ The estimated number of revisions for 1000 patients is 15 for kinematically aligned TKA and 70 and 60, respectively, for the United States and the United Kingdom studies of mechanically aligned TKA. In the study of kinematic alignment, 4 of 7 revisions were associated with excessive flexion of the femoral component (N=3) and reverse slope of the tibial component (N=1) in the sagittal plane. Limiting flexion of the femoral component and restoring the slope of the native tibia could have lowered the incidence of these revisions.^{36,44-46} The postoperative alignment of the tibial component, knee, and limb in varus and valgus outlier ranges according to mechanical alignment criteria does not adversely affect the 10-year implant survival, annual revision rate, and level of function as measured by the Oxford Knee and Western Ontario and McMaster Universities Osteoarthritis Index scores.³⁵ Hence, restoring the native joint lines, Q-angle, and limb alignments unique to each patient results in high long-term implant survival regardless of the degree of preoperative varus–valgus and flexion deformity and postoperative alignment.

CONCLUSION

The philosophy of kinematic alignment and the calipered surgical technique using manual instruments and verification checks accurately sets the femoral and tibial components coincident to the

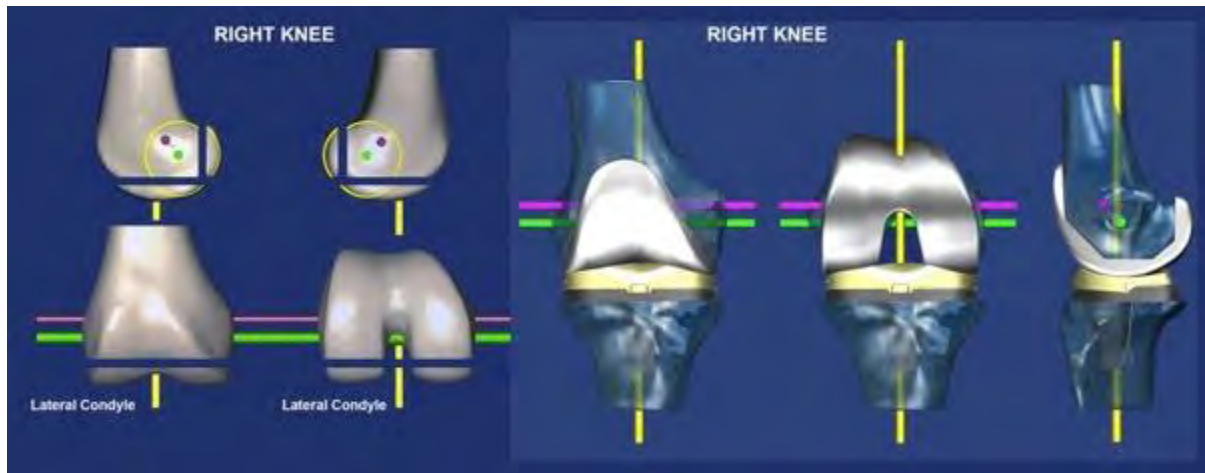
native joint lines. This improves patient outcomes and implant survival.

REFERENCES

1. Coughlin KM, Incavo SJ, Churchill DL, Beynon BD. Tibial axis and patellar position relative to the femoral epicondylar axis during squatting. *J Arthroplasty*. 2003;18(8):1048-1055.
2. Dossett HG, Estrada NA, Swartz GJ, LeFevre GW, Kwasman BG. A randomised controlled trial of kinematically and mechanically aligned total knee replacements: two-year clinical results. *Bone Joint J*. 2014;96-B(7):907-913.
3. Hollister AM, Jatana S, Singh AK, Sullivan WW, Lupichuk AG. The axes of rotation of the knee. *Clin Orthop Relat Res*. 1993;290:259-268.
4. Iranpour F, Merican AM, Baena FR, Cobb JP, Amis AA. Patellofemoral joint kinematics: the circular path of the patella around the trochlear axis. *J Orthop Res*. 2010;28(5):589-594.
5. Nedopil AJ, Singh AK, Howell SM, Hull ML. Does calipered kinematically aligned TKA restore native left to right symmetry of the lower limb and improve function? *J Arthroplasty*. 2018;33(2):398-406.
6. Calliess T, Bauer K, Stukenborg-Colsman C, Windhagen H, Budde S, Ettinger M. PSI kinematic versus non-PSI mechanical alignment in total knee arthroplasty: a prospective, randomized study. *Knee Surg Sports Traumatol Arthrosc*. 2017;25(6):1743-1748.
7. Courtney PM, Lee GC. Early outcomes of kinematic alignment in primary total knee arthroplasty: a meta-analysis of the literature. *J Arthroplasty*. 2017;32(6):2028-2032.
8. Lee YS, Howell SM, Won YY, et al. Kinematic alignment is a possible alternative to mechanical alignment in total knee arthroplasty. *Knee Surg Sports Traumatol Arthrosc*. 2017;25(11):3467-3479.
9. Nam D, Nunley RM, Barrack RL. Patient dissatisfaction following total knee replacement: a growing concern? *Bone Joint J*. 2014;96-B(11)(suppl A):96-100.
10. Li Y, Wang S, Wang Y, Yang M. Does kinematic alignment improve short-term functional outcomes after total knee arthroplasty compared with mechanical alignment? A systematic review and meta-analysis. *J Knee Surg*. 2018;31(1):78-86.
11. Matsumoto T, Takayama K, Ishida K, Hayashi S, Hashimoto S, Kuroda R. Radiological and clinical comparison of kinematically versus mechanically aligned total knee arthroplasty. *Bone Joint J*. 2017;99-B(5):640-646.
12. Nakamura S, Tian Y, Tanaka Y, et al. The effects of kinematically aligned total knee arthroplasty on stress at the medial tibia: a case study for varus knee. *Bone Joint Res*. 2017;6(1):43-51.
13. Waterson HB, Clement ND, Eyres KS, Man-
dalia VI, Toms AD. The early outcome of kinematic versus mechanical alignment in total knee arthroplasty: a prospective randomised control trial. *Bone Joint J*. 2016;98-B(10):1360-1368.
14. Young SW, Walker ML, Bayan A, Briant-Evans T, Pavlou P, Farrington B, The Chitranjan S. Ranawat Award. No difference in 2-year functional outcomes using kinematic versus mechanical alignment in TKA: a randomized controlled clinical trial. *Clin Orthop Relat Res*. 2017;475(1):9-20.
15. Rivière C, Iranpour F, Harris S, et al. The kinematic alignment technique for TKA reliably aligns the femoral component with the cylindrical axis. *Orthop Traumatol Surg Res*. 2017;103(7):1069-1073.
16. Johnson JM, Mahfouz MR, Midillioglu MR, Nedopil AJ, Howell SM. Three-dimensional analysis of the tibial resection plane relative to the arthritic tibial plateau in total knee arthroplasty. *J Exp Orthop*. 2017;4(1):27.
17. Bellemans J, Colyn W, Vandenuecker H, Victor J, The Chitranjan Ranawat Award. Is neutral mechanical alignment normal for all patients? The concept of constitutional varus. *Clin Orthop Relat Res*. 2012;470(1):45-53.
18. Eckhoff DG, Bach JM, Spitzer VM, et al. Three-dimensional mechanics, kinematics, and morphology of the knee viewed in virtual reality. *J Bone Joint Surg Am*. 2005;87(suppl 2):71-80.
19. Niki Y, Nagura T, Nagai K, Kobayashi S, Harato K. Kinematically aligned total knee arthroplasty reduces knee adduction moment more than mechanically aligned total knee arthroplasty. *Knee Surg Sports Traumatol Arthrosc*. 2018;26(6):1629-1635.
20. Shetty GM, Mullaji A, Bhayde S, Nha KW, Oh HK. Factors contributing to inherent varus alignment of lower limb in normal Asian adults: role of tibial plateau inclination. *Knee*. 2014;21(2):544-548.
21. Singh AK, Nedopil AJ, Howell SM, Hull ML. Does alignment of the limb and tibial width determine relative narrowing between compartments when planning mechanically aligned TKA? *Arch Orthop Trauma Surg*. 2018;138(1):91-97.
22. Song MH, Yoo SH, Kang SW, Kim YJ, Park GT, Pyeun YS. Coronal alignment of the lower limb and the incidence of constitutional varus knee in Korean females. *Knee Surg Relat Res*. 2015;27(1):49-55.
23. Gu Y, Howell SM, Hull ML. Simulation of total knee arthroplasty in 5° or 7° valgus: a study of gap imbalances and changes in limb and knee alignments from native. *J Orthop Res*. 2017;35(9):2031-2039.
24. Gu Y, Roth JD, Howell SM, Hull ML. How frequently do four methods for mechanically aligning a total knee arthroplasty cause collateral ligament imbalance and change alignment from normal in white patients? AAOS

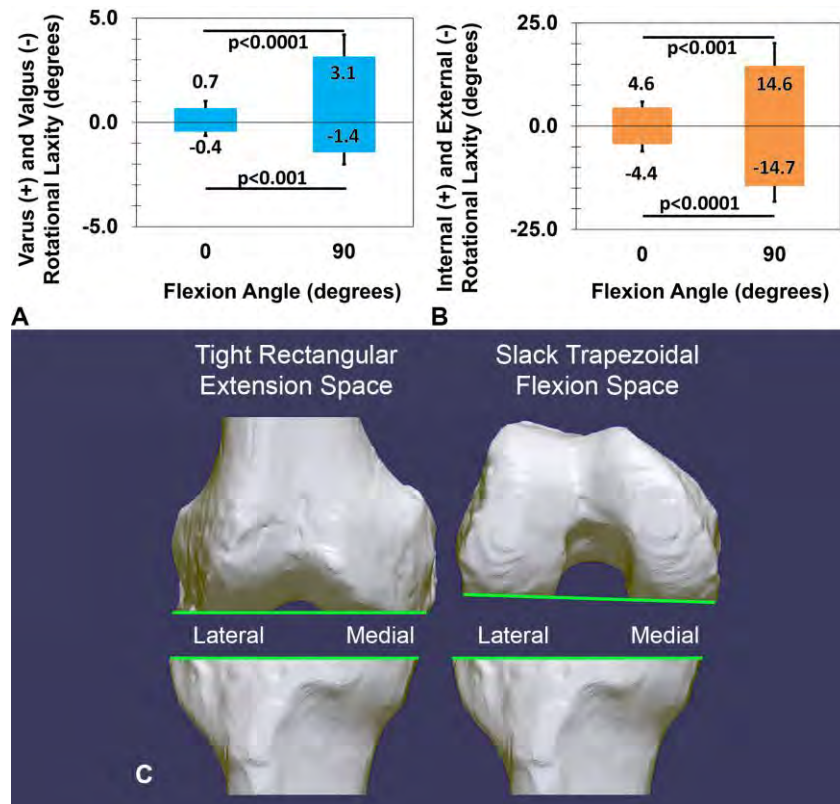
- exhibit selection. *J Bone Joint Surg Am.* 2014;96(12):e101.
25. Delpont H, Labey L, Innocenti B, De Corte R, Vander Sloten J, Bellemans J. Restoration of constitutional alignment in TKA leads to more physiological strains in the collateral ligaments. *Knee Surg Sports Traumatol Arthrosc.* 2015;23(8):2159-2169.
 26. Meneghini RM, Ziemba-Davis MM, Lovro LR, Ireland PH, Damer BM. Can intraoperative sensors determine the “target” ligament balance? Early outcomes in total knee arthroplasty. *J Arthroplasty.* 2016;31(10):2181-2187.
 27. Shelton TJ, Howell SM, Hull ML. Is there a force target that predicts early patient-reported outcomes after kinematically aligned TKA [published online ahead of print December 7, 2018]? *Clin Orthop Relat Res.* doi:10.1097/CORR.0000000000000600.
 28. Shelton TJ, Nedopil AJ, Howell SM, Hull ML. Do varus or valgus outliers have higher forces in the medial or lateral compartments than those which are in-range after a kinematically aligned total knee arthroplasty? Limb and joint line alignment after kinematically aligned total knee arthroplasty. *Bone Joint J.* 2017;99-B(10):1319-1328.
 29. Roth JD, Howell SM, Hull ML. Kinematically aligned total knee arthroplasty limits high tibial forces, differences in tibial forces between compartments, and abnormal tibial contact kinematics during passive flexion. *Knee Surg Sports Traumatol Arthrosc.* 2018;26(6):1589-1601.
 30. Roth JD, Howell SM, Hull ML. Analysis of differences in laxities and neutral positions from native after kinematically aligned TKA using cruciate retaining implants [published online ahead of print November 30, 2018]. *J Orthop Res.* doi:10.1002/jor.24196.
 31. Shelton TJ, Howell SM, Hull ML. A total knee arthroplasty is stiffer when the intraoperative tibial force is greater than the native knee [published online ahead of print November 9, 2018]. *J Knee Surg.* doi:10.1055/s-0038-1675421.
 32. Blakeney W, Clément J, Desmeules F, Hagemeister N, Rivière C, Vendittoli PA. Kinematic alignment in total knee arthroplasty better reproduces normal gait than mechanical alignment [published online ahead of print October 1, 2018]. *Knee Surg Sports Traumatol Arthrosc.* doi:10.1007/s00167-018-5174-1.
 33. Roth JD, Howell SM, Hull ML. Native knee laxities at 0°, 45°, and 90° of flexion and their relationship to the goal of the gap-balancing alignment method of total knee arthroplasty. *J Bone Joint Surg Am.* 2015;97(20):1678-1684.
 34. Verstraete MA, Meere PA, Salvadore G, Victor J, Walker PS. Contact forces in the tibiofemoral joint from soft tissue tensions: implications to soft tissue balancing in total knee arthroplasty. *J Biomech.* 2017;58:195-202.
 35. Howell SM, Shelton TJ, Hull ML. Implant survival and function ten years after kinematically aligned total knee arthroplasty. *J Arthroplasty.* 2018;33(12):3678-3684.
 36. Nedopil AJ, Howell SM, Hull ML. What mechanisms are associated with tibial component failure after kinematically-aligned total knee arthroplasty? *Int Orthop.* 2017;41(8):1561-1569.
 37. Ji HM, Han J, Jin DS, Seo H, Won YY. Kinematically aligned TKA can align knee joint line to horizontal. *Knee Surg Sports Traumatol Arthrosc.* 2016;24(8):2436-2441.
 38. Nedopil AJ, Howell SM, Hull ML. Does malrotation of the tibial and femoral components compromise function in kinematically aligned total knee arthroplasty? *Orthop Clin North Am.* 2016;47(1):41-50.
 39. Nedopil AJ, Howell SM, Rudert M, Roth J, Hull ML. How frequent is rotational mismatch within 0°±10° in kinematically aligned total knee arthroplasty? *Orthopedics.* 2013;36(12):e1515-e1520.
 40. Eckhoff D, Hogan C, DiMatteo L, Robinson M, Bach J. Difference between the epicondylar and cylindrical axis of the knee. *Clin Orthop Relat Res.* 2007;461:238-244.
 41. Howell SM, Kuznik K, Hull ML, Siston RA. Longitudinal shapes of the tibia and femur are unrelated and variable. *Clin Orthop Relat Res.* 2010;468(4):1142-1148.
 42. Howell SM, Papadopoulos S, Kuznik KT, Hull ML. Accurate alignment and high function after kinematically aligned TKA performed with generic instruments. *Knee Surg Sports Traumatol Arthrosc.* 2013;21(10):2271-2280.
 43. Roth JD, Hull ML, Howell SM. The limits of passive motion are variable between and unrelated within normal tibiofemoral joints. *J Orthop Res.* 2015;33(11):1594-1602.
 44. Brar AS, Howell SM, Hull ML, Mahfouz MR. Does kinematic alignment and flexion of a femoral component designed for mechanical alignment reduce the proximal and lateral reach of the trochlea? *J Arthroplasty.* 2016;31(8):1808-1813.
 45. Eittinger M, Calliess T, Howell SM. Does a positioning rod or a patient-specific guide result in more natural femoral flexion in the concept of kinematically aligned total knee arthroplasty? *Arch Orthop Trauma Surg.* 2017;137(1):105-110.
 46. Nedopil AJ, Howell SM, Hull ML. What clinical characteristics and radiographic parameters are associated with patellofemoral instability after kinematically aligned total knee arthroplasty? *Int Orthop.* 2017;41(2):283-291.
 47. Nam D, Lin KM, Howell SM, Hull ML. Femoral bone and cartilage wear is predictable at 0° and 90° in the osteoarthritic knee treated with total knee arthroplasty. *Knee Surg Sports Traumatol Arthrosc.* 2014;22(12):2975-2981.
 48. Howell SM, Chen J, Hull ML. Variability of the location of the tibial tubercle affects the rotational alignment of the tibial component in kinematically aligned total knee arthroplasty. *Knee Surg Sports Traumatol Arthrosc.* 2013;21(10):2288-2295.
 49. Paschos NK, Howell SM, Johnson JM, Mahfouz MR. Can kinematic tibial templates assist the surgeon locating the flexion and extension plane of the knee? *Knee.* 2017;24(5):1006-1015.
 50. Christen B, Heesterbeek P, Wymenga A, Wehrli U. Posterior cruciate ligament balancing in total knee replacement: the quantitative relationship between tightness of the flexion gap and tibial translation. *J Bone Joint Surg Br.* 2007;89(8):1046-1050.
 51. Howell SM, Howell SJ, Kuznik KT, Cohen J, Hull ML. Does a kinematically aligned total knee arthroplasty restore function without failure regardless of alignment category? *Clin Orthop Relat Res.* 2013;471(3):1000-1007.
 52. Howell SM, Papadopoulos S, Kuznik K, Ghaly LR, Hull ML. Does varus alignment adversely affect implant survival and function six years after kinematically aligned total knee arthroplasty? *Int Orthop.* 2015;39(11):2117-2124.
 53. Ritter MA, Davis KE, Meding JB, et al. The effect of alignment and BMI on failure of total knee replacement. *J Bone Joint Surg Am.* 2011;93(17):1588-1596.
 54. Lozano R, Campanelli V, Howell S, Hull M. Kinematic alignment more closely restores the groove location and the sulcus angle of the native trochlea than mechanical alignment: implications for prosthetic design [published online ahead of print October 24, 2018]. *Knee Surg Sports Traumatol Arthrosc.* doi:10.1007/s00167-018-5220-z.
 55. Rivière C, Iranpour F, Harris S, et al. Differences in trochlear parameters between native and prosthetic kinematically or mechanically aligned knees. *Orthop Traumatol Surg Res.* 2018;104(2):165-170.
 56. Parratte S, Pagnano MW, Trousdale RT, Berry DJ. Effect of postoperative mechanical axis alignment on the fifteen-year survival of modern, cemented total knee replacements. *J Bone Joint Surg Am.* 2010;92(12):2143-2149.
 57. Bonner TJ, Eardley WG, Patterson P, Gregg PJ. The effect of post-operative mechanical axis alignment on the survival of primary total knee replacements after a follow-up of 15 years. *J Bone Joint Surg Br.* 2011;93(9):1217-1222.

Figure A



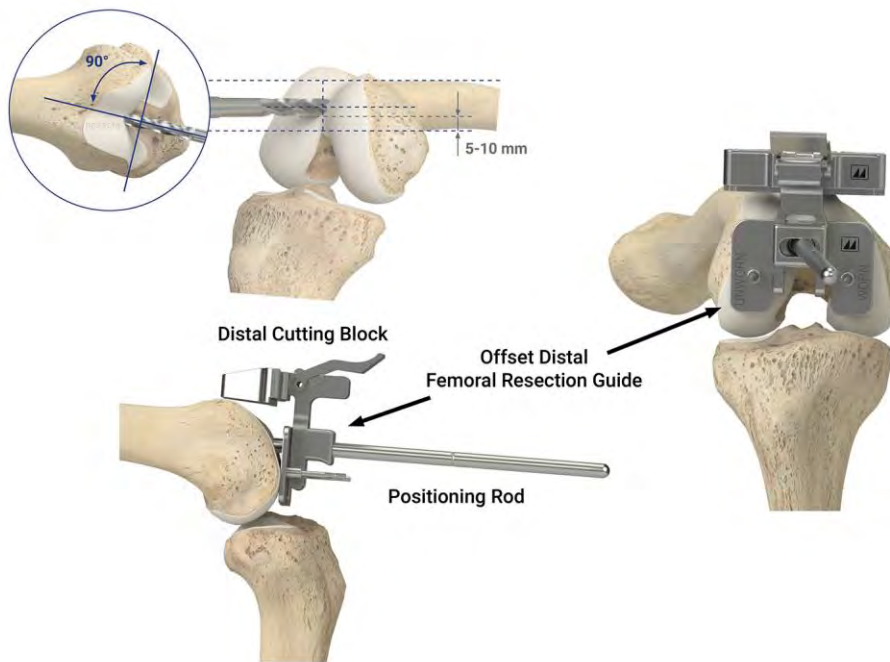
A right femur (left) and kinematically-aligned TKA (right) shows the parallel and perpendicular relationships between the three 'kinematic' axes of the knee, which from the anatomic basis for the philosophy of co-aligning the axes the components with those of the native knee⁴². The flexion-extension axis of the tibia is the green line, the flexion-extension axis of the patella is the magenta line, and the internal-external axis of the tibia is the yellow line. All three axes are closely parallel or perpendicular to the joint lines of the native knee. Resecting bone from the distal and posterior femur condyles equal in thickness to the condyles of the femoral component after compensating for 2 mm of cartilage wear and 1 mm kerf of the saw cut sets the femoral component coincident to the native joint lines and co-aligns the axes.

Figure B



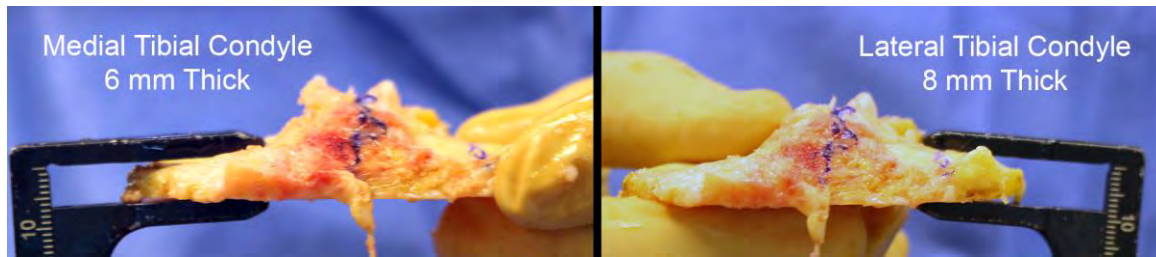
Column graphs show the varus-valgus and internal-external rotational laxities of the native knee are greater at 90° than at 0° of flexion (A and B)^{33,43}. During knee arthroscopy, the surgeon notices these relative differences in laxity as a tight rectangular space when the knee is in extension and a slack trapezoidal space with more laxity laterally than medially when the knee is in flexion. The schematic shows that the resections of the femur and tibia with calipered kinematic alignment restores the tight rectangular extension space and slack trapezoidal flexion space of the native knee (C). Hence, calipered kinematic alignment restores 35 of 40 measures of laxity of the native knee³⁰, whereas the mechanical alignment concept of gap-balancing over-tightens the flexion space that patients may perceive as pain, stiffness, and limited flexion³³.

Figure C



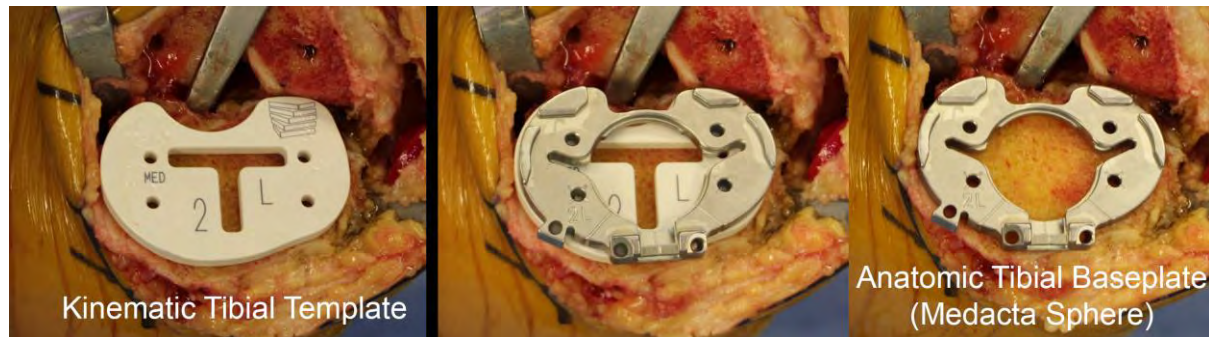
Schematic shows the method for limiting flexion of the femoral component that results in a negligible risk of patellofemoral instability⁴⁴⁻⁴⁶. Start the drill hole midway between the anterior limit of the notch and the anterior cortex of the femur (short blue dotted line). Orient the drill perpendicular to a plane coincident to the distal surface of the femur and parallel with the anterior cortex of the femur. A starting point that keeps a 5-10 mm bone bridge between the posterior rim of the drill hole and the top of the intercondylar notch limits flexion of the femoral component to within $1^{\circ} \pm 2^{\circ}$ with respect to the anatomic axis of the distal femur⁴⁵.

Figure D



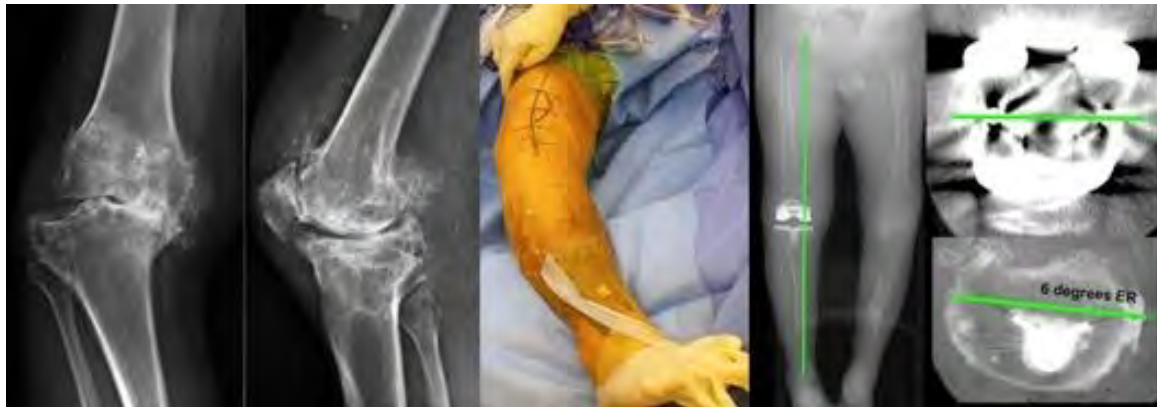Composite of a right knee shows a caliper measuring a 6 mm thick medial tibial condyle and an 8 mm thick lateral tibial condyle at the base of the tibial spines. Expect the medial side to be tight and the lateral side loose when visually examining the varus-valgus laxity between the femoral resection, spacer block, and tibial resection with the knee in full extension. In this case, the use of a 2° varus re-cut guide removed 2 mm of bone from the medial tibial condyle and restored the negligible varus-valgus laxity and tight rectangular space of the native knee in extension (Figure 7) [13, 15]. The negligible varus-valgus laxity verifies the orientation of the tibial component matches the contralateral native limb in 97% of subjects ⁵,

Figure E



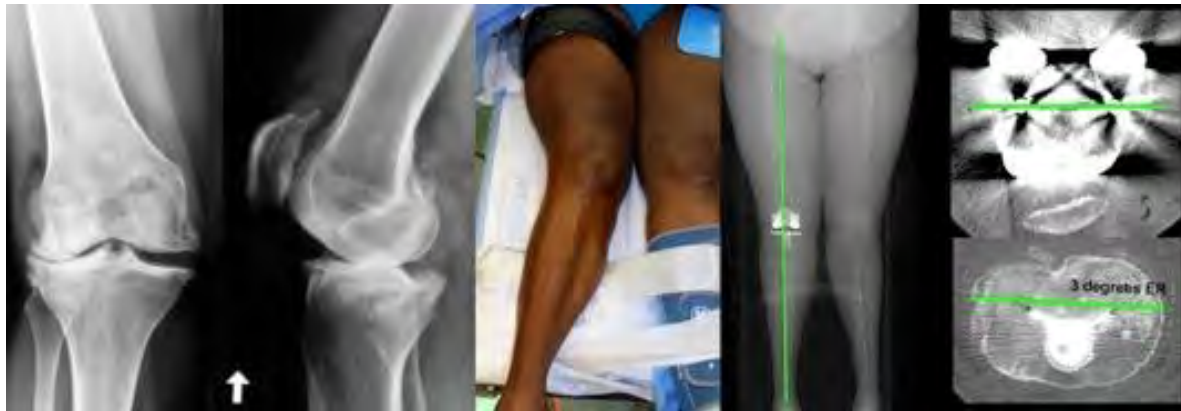Composite of a right knee shows the steps for kinematically aligning internal-external rotation of the tibial component. Best-fitting the largest kinematic tibial template within the cortical boundary of the tibial resection assists the surgeon in accurately setting the I-E rotation of the tibial component parallel to the F-E plane of the knee when performing kinematically-aligned TKA (left)⁴⁹. The anatomic shape of the trial tibial baseplate (Medacta) matches the kinematic tibial template (middle). Best-fitting the largest trial tibial baseplate within the cortical boundary of the tibial resection verifies the internal-external rotation of the tibial component is within $0^{\circ} \pm 4^{\circ}$ of the flexion-extension plane of the knee, which restores high-level knee function (right)^{38, 49}.

Figure F



Composite shows the preoperative radiographs of a post-traumatic knee with a severe varus deformity, flexion contracture and chronic posterior cruciate ligament insufficiency; an intraoperative photograph of the varus deformity; and a postoperative computer tomographic scanogram of the limb and axial views of the femoral and tibial components. The kinematically aligned TKA restored the native alignment and laxities of the knee without a release of the medial collateral ligament and was performed with posterior cruciate ligament substituting implants because of the torn posterior cruciate ligament.

Figure G



Composite shows the preoperative radiographs of the knee with severe valgus deformity, intraoperative photograph of the severe valgus deformity, postoperative computer tomographic scanogram of the limb, and axial views of the femoral and tibial components. The kinematically aligned TKA restored the alignment of the tibial joint line, knee, Q-angle, and limb close to those of the contralateral or native limb without release of the lateral collateral or lateral retinacular ligament in this patient with an intact posterior cruciate ligament.